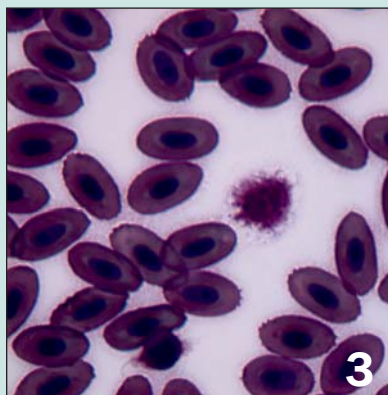


contents



Tamatha A. Patterson, BS, CVT



Scott Stahl, DVM, Dipl ABVP-Avian Practice



M. Scott Echols, DVM, Dipl ABVP-Avian Practice



Megan McCluskey - www.thebettabubble.com/spiny

Observations from the Field

- 3 A Review of Aviacolor: A Stain for Avian Leukocytes**
Tamatha A. Patterson, BS, CVT
- 6 In-house Diagnosis of Sarcocystosis**
Marc Kramer, DVM and Michael Garner, DVM, Dipl ACVP

Case Reports

Peer Reviewed

- 11 Diaphragmatic Kidney Herniation in a Rabbit**
Erik Stauber, DVM, PhD; Nickol Finch, DVM;
Patrick Caplazi, Dr med vet, PhD, Dipl ACVP
- 13 Suspected Zinc Toxicosis in an Iguana**
Erik Stauber, DVM, PhD; Patricia A. Talcott, MS, DVM, PhD, Dipl ABVT
- 15 Interesting Features of Nutritional Secondary Hyperparathyroidism in Two Young Greek Tortoises**
Gerhard Jennemann; Michaela Wettlaufer and
Dr rer nat Hans-J. Bidmon

Observations from the Forum

- 21 Guinea Pig "Cloaca"**
- 22 Review of Rabbit Anesthesia**
- 24 Celecoxib vs Meloxicam**
- 26 Digital Cameras to Document Cases**

Clinician's Notebook

Peer Reviewed

- 27 Management of Avian Renal Disease**
M. Scott Echols, DVM, Dipl ABVP-Avian Practice

Exotic Animal Care

- 36 Domestic Mice**
Susan Leck, DVM, Dipl ABVP-Canine and Feline Practice
- 39 Spiny Mice**
Thomas Ryan, DVM, Dipl ABVP-Avian Practice

Departments

- 43  For Your Bookshelf**
- 46  Exotic Marketplace**